

## CASE REPORT



# A recurrence case of keratocystic odontogenic tumor

Tejavathi Nagaraj, Haritma Nigam, Arundhati Biswas, C. K. Sumana

Department of Oral Medicine and Radiology, Sri Rajiv Gandhi College of Dental Sciences and Hospital, Bengaluru, Karnataka, India

**Correspondence:**

Dr. Haritma Nigam, Department of Oral Medicine and Radiology, Sri Rajiv Gandhi College of Dental Sciences and Hospital, Bengaluru, Karnataka, India.  
E-mail: dr.haritmanigam@gmail.com

Received 20 December 2017;

Accepted: 11 January 2018

doi: 10.15713/ins.ijmdcr.75

**How to cite the article:**

Nagaraj T, Nigam H, Biswas A, Sumana CK.  
A recurrence case of keratocystic odontogenic tumor. Int J Med Dent Case Rep 2017;4:1-4.

**Abstract**

Keratocystic odontogenic tumor is a rare, benign, intraosseous tumor of odontogenic origin with a potential of aggressive and infiltrative behavior. It shows specific histopathological features, and follow-up is characterized by a high rate of recurrence. Moreover, therefore, to reduce the chances of recurrences, along with the surgical modalities like enucleation, chemical and thermal cauterization may be used to deal with the problem of satellite microcysts. We present a case of odontogenic keratocyst with recurrence in a 60-year-old male who reported with the chief complaint of pain in left mandible.

**Keywords:** Enucleation, Keratocystic odontogenic tumor, recurrence**Introduction**

Odontogenic keratocyst (OKC) tumors were first described as a cholesteatoma by Hauer *et al.* in 1926 and the term OKC was firstly coined by Phillipsen in 1956.<sup>[1,2]</sup> OKC was also known as “primordial cyst” by Pindborg and Hansen in 1962 due to its origin from the primordium of the tooth. Later, in 1992, the World Health Organization preferred the term “OKC” for such cysts with a keratinized lining in the histologic grading of odontogenic tumors.<sup>[3]</sup> In 2005, the World Health Organization Classification of the Head and Neck Tumors, the OKC was reclassified from a cystic to a neoplastic lesion and coined the term “keratocystic odontogenic tumor” (KCOT).<sup>[4]</sup>

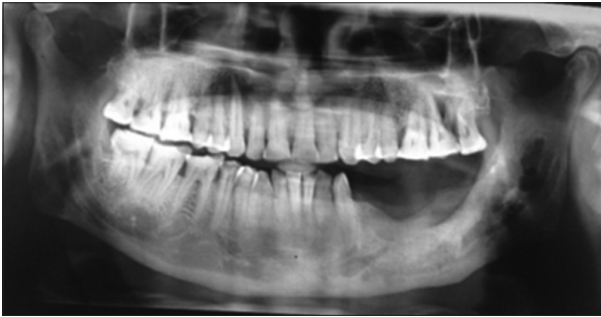It is a benign odontogenic cyst with aggressive behavior and a high recurrence rate of recurrence of 13–62% and is characterized by a large squamous keratinization of its border.<sup>[5,6]</sup> The KCOT contributes approximately 11% of cysts of the jaws and is most commonly located in the mandibular ramus and angle.<sup>[7]</sup>

Clinically, KCOT is demonstrated by an asymptomatic growth. Radiographically, it appears as a well-defined unilocular or multilocular osteolytic lesion which is provisionally diagnosed on the basis of a combined analysis of the medical history, the clinical appearance, and the radiographic appearance and can be confirmed by the histopathology report only. There are various treatment modalities for this type of lesion, and the follow-up is characterized by a high rate of recurrence.<sup>[6]</sup>

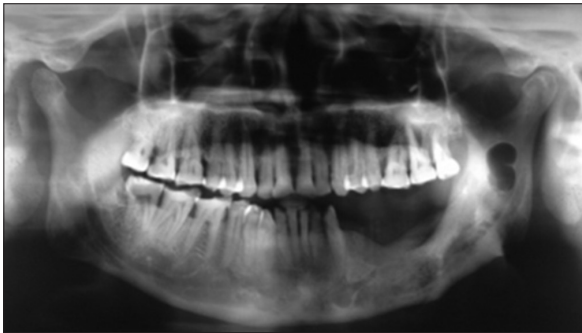
**Case Report**

A 60-year-old male presented to the department of oral medicine and radiology with a complaint of pain in the lower left side of his face since 15 days. Pain was dull, intermittent, radiating toward head. His past medical history was unremarkable. He was a known case of multicystic OKCs in 2008, and after marsupialization of the cysts with the extraction of 34, 35, 36, 37, and 38, BIPP (bismuth subnitrate iodoform) dressing was given for the same and follow-up was done for 1 year, no recurrence was found. Following surgery, 7 years later, the swelling reappeared. He presented with a complaint of swelling with slight discomfort in the mandibular left posterior region which on investigation, panoramic radiograph revealed an increase in radiolucency in relation to both ramus as well as body. For the second time, enucleation was done for the same and there was no complaint of paresthesia or pain in relation to the region of the swelling [Figures 1-3].

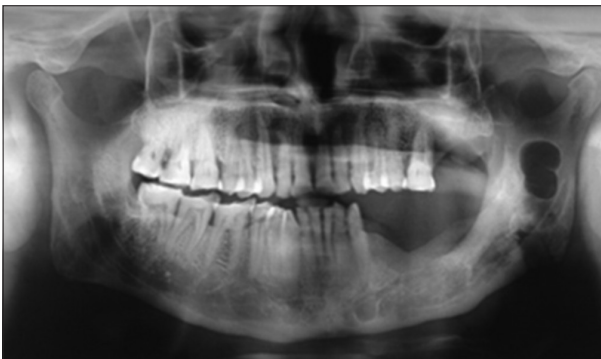Now presently, in 2017, again he reported with a chief complaint of pain on left lower back tooth region. On examination, extraorally, no facial asymmetry was present in the patient [Figure 4]. Intraorally, a fluctuant swelling in the mandibular left posterior region with a diffuse swelling extending to the anterior region measuring about 1 cm × 4 cm in size with obliteration of the buccal vestibule was observed and overlying mucosa was normal [Figure 5]. On palpation, a soft swelling in the premolar region but bony hard on the posterior buccal aspect, with mild expansion of the buccal and lingual plates, extending from mandibular premolar



**Figure 1:** Panoramic radiograph of the patient in 2012



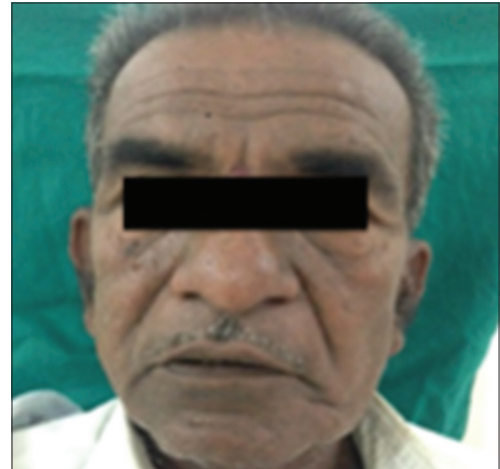**Figure 2:** Panoramic radiograph of the patient in 2015



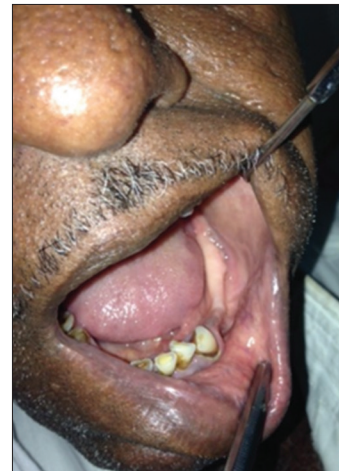**Figure 3:** Panoramic radiograph of the patient in 2016

region to the ascending ramus of mandible on the left side was observed.

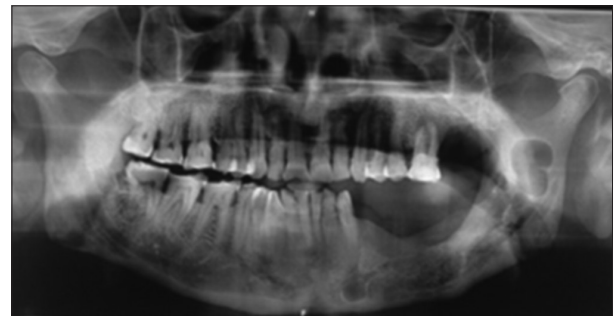Panoramic radiograph was taken which revealed, presence of one multilocular radiolucency on left body and ramus region measuring about 1.5 cm × 2.5 cm in size approximately extending superoinferiorly from 1.5 cm below sigmoid notch to 2 cm above the inferior border of the mandible pushing the mandibular canal inferiorly with well-defined sclerotic borders roughly oval in shape divided by septas giving multilocular appearance and anteroposteriorly 1.5 cm below the alveolar crest to the posterior body of the ramus region suggestive of extraneous type of KCOT. Another well-defined radiolucency was found to be in relation to 33, measuring about 1 cm × 1 cm in size approximately extending superoinferiorly from the apex



**Figure 4:** Front profile view of the patient



**Figure 5:** Intraoral picture depicting missing teeth and vestibular obliteration on left lower buccal vestibule



**Figure 6:** Panoramic radiograph of the patient in 2017

of 33 to 0.5 cm above the inferior border of the mandible and anteroposteriorly from distal 32 to distal 33 with well-defined sclerotic borders suggestive of replacement type of KCOT. Missing teeth were 34, 35, 36, 37, and 38 [Figure 6]. The patient was then advised for enucleation and curettage and chemical cauterization with the use of Carnoy's solution.

## Discussion

The origin of KCOT was generally thought to be derived from either the epithelial remnants of the tooth germ or the basal cell layer of the surface epithelium. The most common age of majority of patients ranges of 20–29 and 40–59, but cases ranging from 5 to 80 years have been reported.<sup>[8]</sup> The distribution between sexes varies from equality to a male-to-female ratio of 1.6:1.<sup>[9]</sup> In the present case, the patient is 60-year-old male. KCOT may occur in any part of the upper and lower jaw with the majority occurring in the mandible, most commonly in the angle of the mandible and ramus.<sup>[10]</sup> In the present case, the site of the occurrence of the pathologic lesion was left body and ramus region.

Radiographically, OKC presents predominantly as an unilocular radiolucency with well-developed sclerotic borders. They may also present as a multilocular radiolucency with a ratio of unilocular to multilocular varying from 3:112 to 1:1.3.<sup>[11]</sup>

In the present case, also of two radiolucencies at different sites, one was multilocular and another was unilocular with well-defined sclerotic borders.

Various studies have shown that KCOT had a recurrence rate of 13–62% and can occur even after the treatment as happened in our present case. Therefore, a long-term follow-up is essential.<sup>[12,13]</sup> During enucleation parts of KCOTs, lining is left in place, which may be expected for lesions with thin and vulnerable walls. It was observed that recurrences are more common in KCOTs which are removed in numerous fragments and also in multilocular lesions and in lesions which had perforated the cortical bone. There are several reasons which are responsible for KCOTs recurrences as following:<sup>[14]</sup>

1. Incomplete removal of the lesions during the surgery,
2. Formation of satellite microcysts within the cystic lining
3. Development of new lesions from epithelial off-shoots of the basal layer of the oral epithelium.
4. Abroptfung phenomenon present (dropping down of the epithelial elements in the connective tissue)
5. Difficult enucleation at the time of surgery.

It was, however, felt that additional treatment was required to remove any small daughter cysts or remnants beyond the visible cyst lining. In an effort to identify this middle course, treatment consisting of techniques ranging from enucleation plus cryosurgery utilized extensively over the past 30 years to enucleation plus Carnoy's solution enucleation with peripheral ostectomy, and more recently, marsupialization and decompression, with various combinations.<sup>[7,15-21]</sup> The chemical and thermal cauterization agents included the use of liquid nitrogen or Carnoy's solution to tackle the problem of retention of the daughter cysts.

Carnoy's solution was first used as a medicament in surgery by Cutler and Zollinger in 1933.<sup>[22]</sup> It was shown to eradicate epithelial rests from the cyst wall. Its average depth of penetration is said to be 1.54 mm after 5 min of application. It contains ferric chloride, glacial acetic acid, chloroform, and absolute alcohol. Carnoy's solution has some disadvantages in that it is not easily obtainable and some of its contents may have side

effects. Chloroform may be carcinogenic as considered by the California Occupational Health and Safety Administration and was banned in 1992 by the US Food and Drug Administration, and the handling of glacial acetic acid requires a high volume fume cupboard. Treatment of the cyst with Carnoy's solution may damage the bone and nerve tissue.<sup>[23]</sup> However, Blanas *et al.* state that application of Carnoy's solution to cyst cavity for 3 min after enucleation should not damage the inferior alveolar nerve. However, several studies showed that usage of Carnoy's solution following enucleation significantly reduces the number of recurrences compared to enucleation alone.<sup>[24-26]</sup> It was seen that, in the present case, initially, two radiolucencies were smaller in size, and later on after 7 years from the beginning, the site of occurrence was the same but with an increment in size.

## Conclusion

Since the patient reported back with a recurrence, a different line of treatment had to be chosen apart from enucleation alone. Therefore, enucleation with the use of an adjunct like Carnoy's solution was decided as a suitable treatment modality in this case. Furthermore, after surgical treatment, periodic post-treatment clinical and radiographic examinations are important for reducing the rate of recurrence.

## References

1. Greenberg MS, Glick M, Ship JA. *Burket's Oral Medicine*. 11<sup>th</sup> ed. Hamilton (Canada): BC Decker; 2008.
2. Khamal AS, Zacariah RK. Under diagnosis of an odontogenic keratocyst - A controversial lesion. *IOSR J Dent Med Sci* 2012;2:37-40.
3. Nayak UA, Rajeshkumar BP, Ahmed J, Baliga MJ. A review of odontogenic keratocyst with a report of unusual occurrence in the maxilla. *Indian J Dent Res* 2002;13:183-6.
4. Philipsen HP. Keratocystic odontogenic tumor. In: Barnes L, Everson JW, Reichart P, Sidransky D, editors. *World Health Organization Classification of Tumors: Pathology and Genetics of Head and Neck Tumors*. Lyon: IARC Publishing Group; 2005. p. 306.
5. Shear M. The aggressive nature of the odontogenic keratocyst: Is it a benign cystic neoplasm? Part 1. Clinical and early experimental evidence of aggressive behaviour. *Oral Oncol* 2002;38:219-26.
6. Shafer WG, Hine MK, Levy BM. *Cysts and tumours of odontogenic origin*. *Oral Pathology*. 6<sup>th</sup> ed. Noida: Elsevier; 2009. p. 254-308.
7. Stoelinga PJ. Long-term follow-up on keratocysts treated according to a defined protocol. *Int J Oral Maxillofac Surg* 2001;30:14-25.
8. Hjorting-Hansen E, Andreassen JO, Robinson LH. A study of odontogenic cysts with special reference to location of keratocysts. *Br J Oral Surg* 1969;7:15-23.
9. El-Hajj G, Anneroth G. Odontogenic keratocysts - A retrospective clinical and histological study. *Int J Oral Maxillofac*

- Surg 1996;25:124-9.
10. Chen CH, Lin CC. Clinical and histopathological study of the odontogenic keratocyst: A follow-up study of 16 cases. *Kaohsiung J Med Sci* 1986;2:601-7.
  11. Woolgar JA, Rippin JW, Browne RM. A comparative study of the clinical and histological features of recurrent and nonrecurrent odontogenic keratocysts. *J Oral Pathol* 1987;16:124-8.
  12. Voorsmit RA, Stoeltinga PJ, van Haelst UJ. The management of keratocysts. *J Maxillofac Surg* 1981;9:228-36.
  13. Pindborg JJ, Hansen J. Studies on odontogenic cyst epithelium. 2. clinical and roentgenologic aspects of odontogenic keratocysts. *Acta Pathol Microbiol Scand* 1963;58:283-94.
  14. Forssell K, Forssell H, Kahnberg KE. Recurrence of keratocysts. A long-term followup study. *Int J Oral Maxillofac Surg* 1988;17:25-8.
  15. Pogrel MA. The use of liquid nitrogen cryotherapy in the management of locally aggressive bone lesions. *J Oral Maxillofac Surg* 1993;51:269-73.
  16. Schmidt BL, Pogrel MA. The use of enucleation and liquid nitrogen cryotherapy in the management of odontogenic keratocysts. *J Oral Maxillofac Surg* 2001;59:720-5.
  17. Irvine GH, Bowerman JE. Mandibular keratocysts: Surgical management. *Br J Oral Maxillofac Surg* 1985;23:204-9.
  18. Pogrel MA. Decompression and marsupialization as a treatment for the odontogenic keratocyst. *Oral Maxillofac Surg Clin North Am* 2003;15:415-27.
  19. Pogrel MA, Jordan RC. Marsupialization as a definitive treatment for the odontogenic keratocyst. *J Oral Maxillofac Surg* 2004;62:651-5.
  20. Pogrel MA. Treatment of keratocysts: The case for decompression and marsupialization. *J Oral Maxillofac Surg* 2005;63:1667-73.
  21. Pogrel MA. Decompression and marsupialization as definitive treatment for keratocysts - A partial retraction. *J Oral Maxillofac Surg* 2007;65:362-3.
  22. Cutler EC, Zollinger R. The use of sclerosing solutions in the treatment of cysts and fistulae. *Am J Surg* 1933;19:411.
  23. US Food and Drug Administration. Section 460.200. In: FDA Compliance Policy Guides. Washington, DC: Food and Drug Administration; 1992. p. 219.
  24. Blanas N, Freund B, Schwartz M, Furst IM. Systematic review of the treatment and prognosis of the odontogenic keratocyst. *Oral Surg Oral Med Oral Pathol Oral Radiol Endod* 2000;90:553.
  25. Johnson NR, Batstone MD, Savage NW. Management and recurrence of keratocystic odontogenic tumor: A systematic review. *Oral Surg Oral Med Oral Pathol Oral Radiol* 2013;116:e271-6.
  26. Zhao YE, Wei JX, Wang SP. Treatment of odontogenic keratocysts: A follow-up of 255 Chinese patients. *Oral Surg Oral Med Oral Pathol Oral Radiol Endod* 2002;94:151-6.